

The Results of ABR in a Child with Noonan Syndrome: Necessity of Renewing the Evaluation Protocols of Syndromes

Bahram Jalaei^{1*}, Mohamad Normani Zakaria²

1. *Audiology Group, School of Rehabilitation Sciences, Iran University of Medical Sciences, Tehran, Iran*
2. *Audiology Program, School of Health Sciences, University of Sains, Kelantan, Malaysia*

Article Info

Received: 2017/03/28
Accepted: 2017/06/05
Published Online: 2017/10/29

DOI:
10.30699/fdisj.01.1.68

How to Cite This Article

Jalaei B, Normani Zakaria M. The Results of ABR in a Child with Noonan Syndrome: Necessity of Renewing the Evaluation Protocols of Syndromes. *Func Disabil J.* 2018; 1 (1): 68-73

Use your device to scan and read the article online



ABSTRACT

55 years after discovering NS, there was not even one publication regarding the use of auditory electrophysiological tests for analyzing the central auditory nervous system in NS patients. This is an attempt to attract attention of scientists and clinicians in using AEPs for evaluating the function of CANS in NS. Readers can find a report about the results of audiological tests and auditory brainstem response (ABR) findings in a 5-year old Malay boy with NS. It should be noted that he could only produce a few meaningful words. The results of audiological tests showed bilateral mild conductive hearing loss at low frequencies. ABR recordings showed good waveform morphology but the results were atypical. That is, absolute latency of wave V was normal but interpeak latencies of waves I-V, I-II, II-III were prolonged. Conversely, interpeak latency of waves III-V was abnormally shorter.

Abnormal ABR results are possibly due to an abnormal anatomical condition or abnormal function of brainstem and might cause speech delay.

Keywords: Auditory brainstem response (ABR), Hearing loss, Speech delay, Noonan Syndrome

Corresponding Information:

Bahram Jalaei, Audiology group, School of Rehabilitation Sciences, Iran University of Medical Sciences, Tehran, Iran. Email: mojtajal@gmail.com

Copyright © 2018, Function and Disability Journal. This is an open-access article distributed under the terms of the Creative Commons Attribution-noncommercial 4.0 International License which permits copy and redistribute the material just in noncommercial usages, provided the original work is properly cited.

Introduction

During a research in 2015, authors of this paper found a patient with Noonan syndrome (NS) with a problem in the middle ear but with delay in speech despite this fact that he was a 5-year-old. A decision was made to repeat all of the audiological tests which had been done in audiology clinic of hospital of University Sains Malaysia (HUSM). For this purpose, the patient was invited for an appointment on 2 July 2015. The patient referred to an audiology clinic and audiological tests were done for him after a written informed consent by his parents.

In 1962, Dr. Jacqueline Anne Noonan identified 9

patients with skeletal malformations, significant chest deformities, pulmonary stenosis and faces that were remarkably similar and had short stature. NS is present in about 1 in 1000 to 1 in 2500 live birth (Noonan & O'Conner, 1996; Burgt, 2007). These patients also have congenital heart defects and could be familial (Romano et al. 2010). This condition was associated with normal chromosomes and occurred in both genders. Furthermore, these patients have widely spaced eyes which are usually pale blue or blue-green in color, distinctive facial features such as a deep groove in the area between the nose and mouth (philtrum), and low-set ears that are rotated backward. People with

NS may have a high arch in the roof of the mouth (high-arched palate), poor alignment of the teeth, and a small lower jaw. Low-set ears that are rotated backward is another sign in NS patients. Both children and adults may have excess neck skin (also called webbing) and a low hairline at the back of the neck. Although patients with NS are usually of normal length and weight at birth, but for most of them growth slows over time and thus almost 50 to 70 percent of patients with NS have short statures (Nora et al., 1974; Mendez et al., 1985; Sharland et al., 1992).

There are some reports about the presence of hearing loss in NS. In the study of Sharland et al. (1992) they found abnormal hearing in 40% of 151 patients with NS. Cremers reported perceptible hearing loss and mental retardation in two patients with NS (Cremers et al., 1992). Heller reported bilateral nerve deafness in one patient with NS (Heller, 1965). Miura had a histopathological study on left temporal bones of 3 patients with NS after their death (Miura et al., 2001). Their study showed that conductive and sensorineural hearing loss could be related to mesenchymal tissue in the middle ear and endolymphatic hydrops in the inner ear, respectively. However, they also found abnormalities in the inner ear and central auditory nervous system (CANS). Recently, Trier reported that a great percentage of NS subjects had external ear anomalies, conductive and sensorineural hearing losses (Trier et al., 2015).

There are very few studies to investigate auditory brainstem function in NS. The first diagnostic study with ABR has been done by the authors and has already been published. Herein, the authors report the result of the analysis of auditory brainstem response in this patient and trying to focus attention of researchers to revise the protocols of evaluation of NS patients using auditory electrophysiological tests properly.

Case Report

As already mentioned, this is a case of 5-year-old Malay boy who was born on June 24, 2009. According to the report of the genetic department of HUSM, he is apparently a normal male karyotype 46, XY [25] but was diagnosed clinically as NS at the age of 18

months. The report of pediatric clinic has shown a soft dimorphism including down slanting palpebral fissures, hypertelorism, low hair line, bilateral epicanthic folds and deformed upper part of both pinna (Fig. 1). He was able to walk at 16 months and run at 17 months. Around this age, he was also able to climb stairs with help. According to the report of the otolaryngology clinic, at the age of 5 years, he can only understand simple commands. In addition, he could only pronounce a few meaningful words, which shows there is a great delay in expressive language. There is no evidence of mental retardation and expressive aphasia.

The patient came to the audiology clinic at the faculty of Health of USM on July 2, 2015 and after written informed consent by his parents, basic audiological evaluation was done. The results of play audiometry showed bilateral mild conductive hearing loss (CHL) while tympanometry showed type B tympanogram (with a rounded peak) in both ears (Fig 2). Acoustic reflex testing was conducted and no reflexes were recorded at the tested frequencies (0.5, 1 and 2 kHz). Recording distortion product otoacoustic emission (DPOAE) showed good outer hair cell emissions were noted at high frequencies (2 to 5 kHz) in both ears.

ABR was then performed to determine the brainstem status of the child. A two-channel Biologic Navigator Pro system (Natus Medical Inc., Mundelein, USA) was used to record ABR with clicks. Montage of four electrodes on his head was done including: non-inverting on the vertex, inverting on each mastoid and ground on the forehead. The electrodes impedance was kept below 3 k Ω throughout the testing.

Before starting the test, a proper instruction was given to the child. During the testing, the subject lied comfortably on the provided bed in the sound proof room. ABR test was performed by placing the headphones on his head and 2000 stimuli were presented at 75 dBnHL in monaurally mode to each ear. The stimulus rate was set at 10.3/s. The time window was set at 15 ms with a 1.21 ms pre-stimulus period. The recording was repeated with other polarities and at least twice for each trial. The acquired responses were amplified 100,000 times and band-pass filtered

at 100-3000 Hz.

The ABR morphology (Fig 3) was unremarkable in both ears, as well as for different stimulus polarities. Table 1 shows the values of ABR absolute latency and interpeak latencies (IPLs). The ABR results of a normal age-equivalent child are also revealed within brackets. According to data in Table 1, the absolute latency of wave V (SD: ± 0.2 ms) for the NS child was essentially similar to that of a normal child in both ears. The most important finding in the ABR result of the NS child (in comparison to a normal child) is the slightly and markedly prolongation of IPLs of I-V, I-II and II-III, respectively (Hall, 2015). Interestingly, the IPL of III-V (SD: ± 0.2 ms) was much shorter in the NS child than in the normal child in both ears. For example, in the right ear, for clicks stimulation

with rarefaction polarity, the IPL of III-V was 1.50 ms (abnormal shortening) for the NS child, meanwhile for normal child was 1.89 ms. In addition, the good diagnostic value of alternating clicks in recording ABR was also revealed. As shown in Table 1, for IPL of III-V, the alternating clicks stimulation showed more consistent results than that of rarefaction clicks in both ears.

Based on the routine hearing tests, there was clear evidence that the child had conductive hearing loss. He was then referred to an otorhinolaryngologist for medical treatment. Due to the remarkable results in ABR, he was also referred for head imaging to verify the findings of ABR. He has been having regular visits to a speech pathology clinic to improve his speech and language abilities.

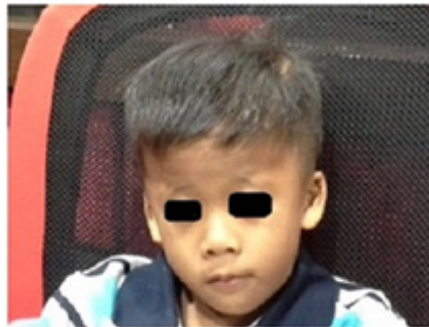

Fig 1. Facial characteristic of the 5-year old malay boy with NS




Fig2. Play audiometry and Tympanometry results of the child with NS

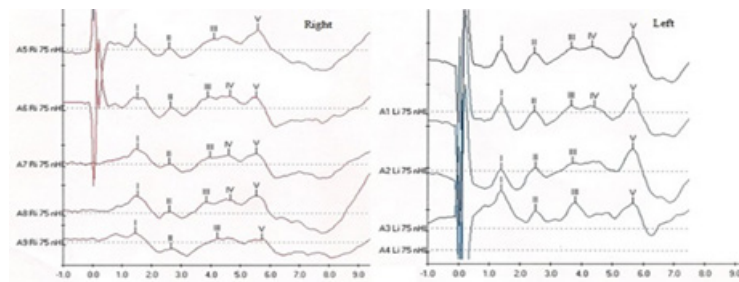


Fig 3. ABR results for the child with NS

Table 1. Absolute latency and interpeak latencies of ABR peaks for the NS child and the respective normal child (in bracket) in left and right ears.

Ear	Polarity	Absolute latency V (ms)	Interpeak latency I – V (ms)	Interpeak latency I – III (ms)		Interpeak latency III – V (ms)
				I – III (ms)		
				I – II (ms)	II – III (ms)	
Right	Rare	5.60 (5.59)	4.13 (3.98)	1.13 (0.96)	1.50 (1.13)	1.50 (1.89)
	Cond	5.54	4.00	1.13	1.25	1.62
	Alt	5.54 (5.51)	4.00 (3.85)	1.06 (0.94)	1.38 (1.08)	1.56 (1.83)
Left	Rare	5.67 (5.64)	4.25 (3.93)	1.06 (0.9)	1.19 (1.12)	2.00 (1.91)
	Cond	5.67	4.25	1.13	1.25	1.87
	Alt	5.60 (5.58)	4.19 (3.86)	1.12 (0.96)	1.38 (1.06)	1.69 (1.84)

Discussion

Audiological tests show a mild conductive hearing loss in both ears of this child but he has delay in speech. As a review on the result: Play audiometry found mild CHL at low frequencies in both ears, which has consistency with the results of tympanometry, acoustic reflex and otoacoustic emission. There are some reports regarding the occurrence of CHL in NS which is possibly due to the presence of remaining mesenchymal tissue in the middle ear and mastoid (Takahara & Sando, 1987; Miura, et al., 2001).

In ABR, there is a good morphology, but analyzing the results show atypical changes in IPLs. That is, with the presence of CHL, the absolute latency of wave V was normal but the IPL were delayed (except for waves III-V which is diminished). Typically, ABR with delay in absolute latencies and normal IPLs are expected in CHL cases. For instance, according to Matas et al. (2005) most of the subjects with CHL revealed the prolongation of absolute latencies of waves I, III and V and normal IPLs. This disagreement is perhaps due to stimulus issue. It should be noted that with using clicks stimuli, the ABR results would represent high frequency information. As shown in audiogram, at high frequencies, the hearing level was generally within the normal range (except a slight loss in 4k Hz). Thus, CHL that occurs at low frequencies might not affect the ABR waveforms with clicks stimulation (Hall, 2015).

The near-normal IPLs of I-V is contributed by the slight delayed IPLs of I-II and even more prolonged IPLs of II-III. Surprisingly, the IPL of III-V was ab-

normally shorter in NS child than in the normal subject. Herein, the abnormality in ABR outcomes in NS child is perhaps due to abnormal anatomical condition of the auditory brainstem (e.g. compromised auditory nerve and/or cochlear nucleus). This is possible as head deformities are common in NS where CANS functions can also be affected.

As seen, analyzing of the ABR results of this NS child has indirectly indicated that some deformities/malfunctions in his CANS that has not been discussed before. In addition, there are at least 4 or 5 other auditory electrophysiological tests that could be done for this child. For instance, the authors have recorded the speech evoked-ABR (sABR) test for this NS child but the authors do not intend to discuss the results of sABR in this paper.

Furthermore, recording other auditory electrophysiological tests can provide more information about the CANS. Recall that there are also many syndrome disorders like NS, where hearing loss is one of the signs of those syndromes and still, many of the aspects of those syndromes have not yet been discovered. Herein, it should be noted that the first publication of the authors about this NS child is the first publication about NS which focused on analyzing the ABR recordings of an NS patient. That is, after 54 years, this is the first publication regarding the diagnostic usage of ABR with NS subjects. In the other words, the authors of this article believe that the evaluation protocols of the syndromes with structural abnormalities along with sensorineural hearing loss should be revised.

Conclusion

The abnormalities in the brainstem and perhaps other parts of CANS might contribute to poor speech development in this NS child. In addition, delay in speech can be the result of a delay in the maturation of the nervous system as well (Kao, 1999). Nonetheless, further studies are guaranteed to systematically investigate this issue. ABR and other auditory electrophysiological tests have good diagnostic values in determining the extent of structural abnormalities of the CANS in NS and other similar conditions involving head de-

formities. When performing ABR, alternating clicks should be included in the test protocol. ABR and other types of auditory evoked potentials (AEPs) should be used routinely when testing special populations.

Acknowledgments

We appreciate cooperation of participant and his family in this study. There was no funding support.

Conflict of Interest

Authors declared no conflict of interest.

References

- Burgt, I.V.D. (2007) Noonan Syndrome. *Orphanet Journal of Rare Diseases*, 2(4).
- Cremers, C.W., Van der Burgt, C.J. (1992) Hearing loss in Noonan syndrome. *Int J Pediatr Otorhinolaryngol*, 23(1), 81- 84.
- Hall, J. (2015) *eHandbook of auditory evoked responses*. Boston Mass: Pearson.
- Heller, R.H. (1965) The Turner phenotype in the male. *The journal of Pediatrics*. 66(1), 48-63.
- Kao, C.P. (1999) Evaluation and management of the child with speech delay. *Am Fam Physician*. 59(11) :3121-3128.
- Matas, C.G., Leite, R.A., Goncalves, I.C., Neves, I.F. (2005) Brainstem Auditory Evoked Potential in Individuals with Conductive and Sensorineural Hearing Losses. *Int Arch Otorhinolaryngol*. 9 (4), 337-347.
- Mendez, H.M.M., Optiz, J.M. (1985) Noonan Syndrome: a review. *Am J Med Genet*. 21(3), 493- 506.
- Miura, M., Sando, I., Orita, Y., Hirsch, B.E. (2001) Temporal bone histopathological study of Noonan syndrome. *Int Journal of Pediatric Otorhinolaryngology*. 60, 73-82.
- Noonan, J.A. & O'Conner. (1996) Noonan syndrome: a clinical description emphasizing the cardiac findings. *Acta Paediatrica Japonica*, 38, 76-83.
- Nora, J.J., Nora, A.H., Sinha, A.K. et al. (1974) The Ullrich-Noonan syndrome (Turner phenotype). *Am J Dis Child*. 127(1), 48-55.
- Romano, A.A., Allanson, J.E., Dahlgren, J. et al. (2010) Noonan Syndrome: Clinical Features, Diagnosis and Management Guidelines. *Amer Acad Paediatrics*, 126 (4), 746-759.
- Sharland, M., Burch, M., McKenna, W.M., Patton, M.A. (1992) A clinical study of Noonan Syndrome. *Arch Dis Child*, 67, 178-183.

ضرورت نیاز به تجدید ارزیابی پروتکل سندرم‌ها: نتایج ABR در یک کودک مبتلا به

سندرم Noonan

بهرام جلائی^{۱*}، محمد نورمانی ذکر یا^۲

۱. گروه شنوایی شناسی، دانشکده علوم توانبخشی، دانشگاه علوم پزشکی ایران، تهران، ایران
۲. گروه شنوایی شناسی، دانشکده علوم بهداشت، دانشگاه سینز مالزی، کلاتان، مالزی

اطلاعات مقاله

چکیده

تاریخ وصول: ۱۳۹۶/۰۱/۰۳
تاریخ پذیرش: ۱۳۹۶/۰۳/۱۵
انتشار آنلاین: ۱۳۹۶/۰۸/۰۷

طی ۵۵ سال پس از کشف سندرم نونان، تاکنون مقاله‌ای درباره استفاده از تست‌های الکتروفیزیولوژی شنیداری، برای تحلیل سیستم اعصاب شنیداری در افراد مبتلا به این سندرم وجود نداشته است. این مقاله می‌کوشد توجه محققان را به استفاده از AEPها، با هدف ارزیابی عملکرد CANS در این سندرم جلب کند. در یک کودک ۵ساله مبتلا به سندرم نونان تست‌های شنیداری و پاسخ شنیداری ساقه مغز بررسی شد. گفتنی است که او تنها می‌توانست چند کلمه معنی‌دار تولید کند. نتایج تست‌های شنیداری نشان داد کاهش متوسط شنیداری هدایت‌کننده دوطرفه در فرکانس‌ها پایین است. ثبت ABR نشان‌دهنده مورفولوژی خوب موج اما آتیبیکال بود؛ به این معنی که تأخیر مطلق موج V طبیعی بود، اما تأخیرهای بین دو موج I-II، II-III و I-V طولانی بود. برعکس، تأخیر اینتر پیک امواج III-V به صورت غیرطبیعی کوتاه‌تر بود.

نتایج غیرطبیعی ABR می‌تواند ناشی از وضعیت‌های غیرطبیعی آناتومیک یا عملکرد غیرطبیعی ساقه مغز باشد و ممکن است باعث تأخیر در گفتار شود.

نویسنده مسئول:

بهرام جلائی

گروه شنوایی شناسی، دانشکده
علوم توانبخشی، دانشگاه علوم
پزشکی ایران، تهران، ایران

پست الکترونیک:

mojtajal@gmail.com

واژه‌های کلیدی: پاسخ شنیداری ساقه مغز (ABR)، کاهش شنیداری، تأخیر در گفتار، سندرم نونان